

## Video Article

# Multispectral Real-time Fluorescence Imaging for Intraoperative Detection of the Sentinel Lymph Node in Gynecologic Oncology

Lucia M.A. Crane<sup>1</sup>, George Themelis<sup>2</sup>, Tim Buddingh<sup>1</sup>, Niels J. Harlaar<sup>1</sup>, Rick G. Pleijhuis<sup>1</sup>, Athanasios Sarantopoulos<sup>2</sup>, Ate G.J. van der Zee<sup>3</sup>, Vasilis Ntziachristos<sup>2</sup>, Gooitzen M. van Dam<sup>1</sup>

<sup>1</sup>Department of Surgery, Division of Surgical Oncology, University Medical Center Groningen

<sup>2</sup>Helmholtz Zentrum, Technical University Munich

<sup>3</sup>Department of Obstetrics and Gynaecology, University Medical Center Groningen

Correspondence to: Gooitzen M. van Dam at [g.m.van.dam@chir.umcg.nl](mailto:g.m.van.dam@chir.umcg.nl)

URL: <http://www.jove.com/index/Details.stp?ID=2225>

DOI: 10.3791/2225

Citation: Crane L.M., Themelis G., Buddingh T., Harlaar N.J., Pleijhuis R.G., Sarantopoulos A., van der Zee A.G., Ntziachristos V., van Dam G.M. (2010). Multispectral Real-time Fluorescence Imaging for Intraoperative Detection of the Sentinel Lymph Node in Gynecologic Oncology. *JoVE*. 44. <http://www.jove.com/index/Details.stp?ID=2225>, doi: 10.3791/2225

## Abstract

The prognosis in virtually all solid tumors depends on the presence or absence of lymph node metastases.<sup>1-3</sup> Surgical treatment most often combines radical excision of the tumor with a full lymphadenectomy in the drainage area of the tumor. However, removal of lymph nodes is associated with increased morbidity due to infection, wound breakdown and lymphedema.<sup>4,5</sup> As an alternative, the sentinel lymph node procedure (SLN) was developed several decades ago to detect the first draining lymph node from the tumor.<sup>6</sup> In case of lymphogenic dissemination, the SLN is the first lymph node that is affected (Figure 1). Hence, if the SLN does not contain metastases, downstream lymph nodes will also be free from tumor metastases and need not to be removed. The SLN procedure is part of the treatment for many tumor types, like breast cancer and melanoma, but also for cancer of the vulva and cervix.<sup>7</sup> The current standard methodology for SLN-detection is by peritumoral injection of radiocolloid one day prior to surgery, and a colored dye intraoperatively. Disadvantages of the procedure in cervical and vulvar cancer are multiple injections in the genital area, leading to increased psychological distress for the patient, and the use of radioactive colloid.

Multispectral fluorescence imaging is an emerging imaging modality that can be applied intraoperatively without the need for injection of radiocolloid. For intraoperative fluorescence imaging, two components are needed: a fluorescent agent and a quantitative optical system for intraoperative imaging. As a fluorophore we have used indocyanine green (ICG). ICG has been used for many decades to assess cardiac function, cerebral perfusion and liver perfusion.<sup>8</sup> It is an inert drug with a safe pharmaco-biological profile. When excited at around 750 nm, it emits light in the near-infrared spectrum around 800 nm. A custom-made multispectral fluorescence imaging camera system was used.<sup>9</sup>

The aim of this video article is to demonstrate the detection of the SLN using intraoperative fluorescence imaging in patients with cervical and vulvar cancer. Fluorescence imaging is used in conjunction with the standard procedure, consisting of radiocolloid and a blue dye. In the future, intraoperative fluorescence imaging might replace the current method and is also easily transferable to other indications like breast cancer and melanoma.

## Protocol

### 1. Intraoperative Multispectral Fluorescence Camera

1. A custom-made camera system was developed at developed at the Institute for Biological and Medical Imaging (IBMI, Technical University / Helmholtz Zentrum, Munich, Germany) in close in collaboration with SurgOptix (SurgOptix Inc, Redwood Shores, CA, USA). The setup of the intraoperative multispectral fluorescence camera system is shown in Figure 2.
2. Light passes through a system of optics and is separated into visible light, light at the emission (fluorescence) wavelength band and light at the excitation wavelength band. These bundles are detected by CCD-cameras (CCD) (Figure 2). Multi-spectral signals from all cameras are processed in order to correct for artifacts and yield true quantitative fluorochrome bio-distribution. Color and fluorescence signals can be displayed as separate images on external monitors or superimposed in one image.
3. The excitation and emission filters of the camera are set in the measurement herein to collect at 750 nm and 800 ±20 nm respectively.

### 2. Optical Contrast Agent Preparation

1. The fluorescent contrast agent indocyanine green (ICG, Pulsion AG, Munich, Germany) is prepared under sterile conditions. A concentration of 0.5 mg/mL is used. It is important to use sterile distilled water and not sodium chloride (NaCl), as the latter will cause the ICG to aggregate.
2. After preparation, the solution must be stored in a dark, cool place to avoid fast deterioration of the fluorescence intensity by bleaching. Note: from this point forward keep the ICG protected from light.

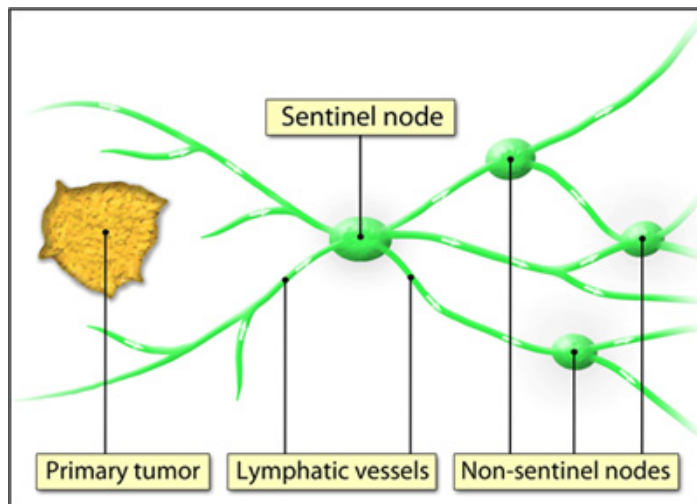
### 3. Intraoperative Imaging - Setup and Injection of ICG

1. The camera is positioned and initiated in the operating theatre prior to surgery to minimize interference with the standard surgical procedure, and connected to the high-definition screens (Figure 2B).
2. The camera is covered in standard sterile drapes (Carl Zeiss Vision BV, Sliedrecht, the Netherlands, OPMI Drape REF 306071) by the investigator in sterile OR clothing.
3. Note: care is taken to use only clear disinfecting agents, as colored disinfecting agents are often autofluorescent and might interfere with the imaging procedure. Moreover, sterile drapes and surgical markers can be autofluorescent. It is advised to test all materials used in the OR and the operating field for autofluorescence prior to surgery.

4. The fluorescent contrast agent indocyanine green (ICG) is prepared under sterile conditions. A concentration of 0.5 mg/mL is used. It is important to use sterile distilled water and not NaCl, as the latter will cause the ICG to aggregate. After preparation, the solution must be stored in a dark, cool place to avoid fast deterioration of the fluorescence intensity. Note: it is advisable to change gloves after preparing ICG, as even a small amount of spill of ICG may influence the image quality.
5. The imaging procedure starts after opening the abdomen. When the area of interest is exposed, the camera is maneuvered into the operating field. The zoom and focus are adjusted under sterile conditions. Lights in the operating theatre are switched off for better detection of the fluorescence signal.
6. 1.0 mL of 0.5 mg/mL ICG is mixed with 1.0 mL of the standard blue dye (patent blue / bleu patenté, Guerbet, France) in one syringe. The surgeon injects the contrast agent in four quadrants around the primary tumor, preventing spill of the agent. Note: in case of spill of ICG on the surgical gloves, it is necessary to change gloves. Still images or real-time videos are acquired of the lymph flow and the appearance of the fluorescent sentinel lymph node (Figure 3). All images and videos are directly saved on the computer.
7. Apart from fluorescence, the SLN is also detected according to the standard protocol, either using a gamma probe or by visual inspection for a blue discoloration, or both. The radioactive tracer is generally administered one day prior to surgery, after which a lymphoscintigram is performed for detection of a radioactive SLN. This is part of the standard procedure and has no place in the fluorescence imaging protocol.
8. Real-time excision of the SLN is guided by both fluorescence and blue discoloration of lymph nodes. The real-time feature of the camera helps to detect for any remnant fluorescence or unexpected localizations of fluorescent nodes.
9. After excision of the SLN, *ex vivo* images are acquired of all excised lymph nodes for the presence of a fluorescent signal. The exposure time can be prolonged for higher resolution when capturing still images (Figure 4).
10. Histopathological examination of the lymph nodes reveals the presence or absence of tumor cells in the sentinel lymph node.

## 4. Representative Results

Fluorescent lymph nodes can be detected with a high signal-to-background ratio. Also, flow of ICG through lymphatic vessels can be monitored allowing real-time lymph node mapping. Results may be influenced by increasing depth of the node, possibly requiring different illumination procedures to achieve detection. Future application of specific tumor targeted fluorescent agents may provide intraoperative detection of a positive SLN with cancer cells using this technology.



**Figure 1. The sentinel lymph node (SLN) theory.** The SLN is the first draining lymph node(s) from the tumor.

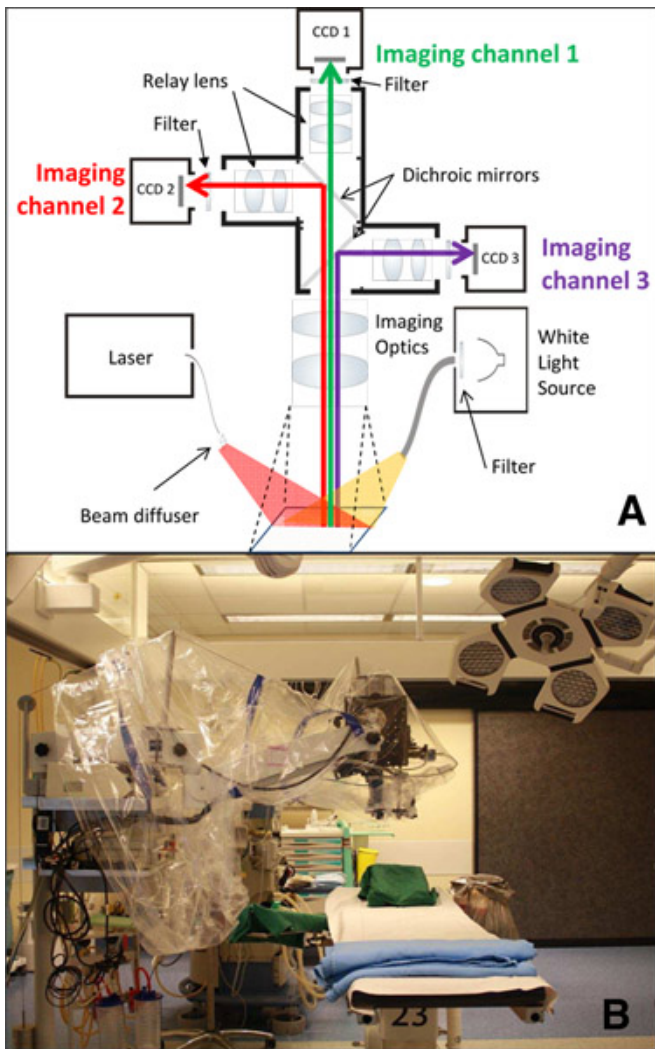


Figure 2. Schematic picture of the multispectral fluorescence camera system (A). The basic setup of the camera system in the operating theatre (B).

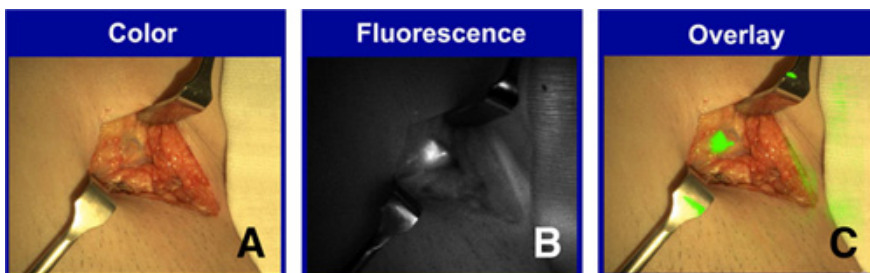


Figure 3. Multispectral fluorescence imaging of a lymph node in vulvar cancer. Color image of a lymph node *in vivo* (A). Fluorescence image of the same lymph node, *in vivo* (B). Pseudocolor fluorescence image superimposed on the color image (C).

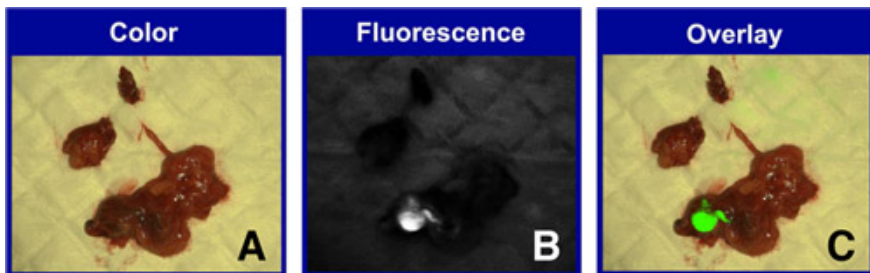


Figure 4. Multispectral fluorescence imaging of a lymph node *ex vivo* in cervical cancer. Color image of a lymph node *ex vivo* (A). Fluorescence image of the same lymph node, *ex vivo* (B). Pseudocolor fluorescence image superimposed on the color image (C).

## Disclosures

VN and GMvD are member of the scientific board of SurgOptix Inc. Prior to the procedure, the research protocol is approved by the local Investigational Review Board (IRB) and informed consent from the patient is acquired.

## Discussion

This video demonstrates the application of multispectral intraoperative fluorescence imaging technology for intraoperative detection of the sentinel lymph node (SLN) in gynecologic oncology. The methodology has certain advantages over the conventional SLN procedure. The injection takes place during the surgical procedure itself with the patient anesthetized rather than a day prior to surgery, which is more patient-friendly, especially in gynecologic cancers. Furthermore, intraoperative imaging provides the surgeon with direct visual feedback of the lymph flow and its drainage pattern to the SLN, rather than indirectly via a Geiger-teller. In cervical cancer, where lymph nodes are located deep in the pelvis, this may help improve detection.

Nonetheless, the greatest significance lies in the step-up approach towards targeted imaging. Targeted fluorescent contrast agents may be fused with tumor-specific antibodies or substrates specifically directed at tumor cells. In this manner, intraoperative fluorescence imaging has great potential to radically alter the current practice of oncologic surgery.

## Acknowledgements

We are indebted to Mrs. Ina Wesselman for training and planning of the OR personnel.

## References

1. Tinga, D.J., Bouma, J., & Aalders, J.G. Patients with squamous cell versus adeno(squamous) carcinoma of the cervix, what factors determine the prognosis? *Int J Gynecol Cancer* 2(2), 83-91 (1992).
2. McMahon, C.J., Rofsky, N.M., Pedrosa, I. Lymphatic metastases from pelvic tumors: anatomic classification, characterization, and staging. *Radiology* 254(1), 31-46 (2010).
3. Zivanovic, O., Khoury-Collado, F., Abu-Rustum, N.R., & Gemignani, M.L. Sentinel lymph node biopsy in the management of vulvar carcinoma, cervical cancer, and endometrial cancer. *Oncologist* 14(7), 695-705 (2009).
4. Fuller, J., Guderian, D., Kohler, C., Schneider, A., & Wendt, T.G. Lymph edema of the lower extremities after lymphadenectomy and radiotherapy for cervical cancer. *Strahlenther Onkol* 184(4), 206-11 (2008).
5. Ayhan, A., Celik, H., & Dursun, P. Lymphatic mapping and sentinel node biopsy in gynecological cancers: a critical review of the literature. *World J Surg Oncol* 6, 53 (2008).
6. Tanis, P.J., Nieweg, O.E., Valdes Olmos, R.A., Rutgers, E.J., & Kroon, B.B. History of sentinel node and validation of the technique. *Breast Cancer Res* 3(2), 109-12 (2001).
7. El Ghobashy, A.E., & Saidi, S.A. Sentinel lymph node sampling in gynaecological cancers: techniques and clinical applications. *Eur J Surg Oncol* 35(7), 675-85 (2009).
8. Alford, R., Simpson, H.M., Duberman, J., Hill, G.C., Ogawa, M., & Regino, C., *et al.* Toxicity of organic fluorophores used in molecular imaging: literature review. *Mol Imaging* 8(6), 341-54 (2009).
9. Themelis, G., Yoo, J.S., Soh, K.S., Schulz, R., & Ntziachristos, V. Real-time intraoperative fluorescence imaging system using light-absorption correction. *J Biomed Opt* 14(6), 064012 (2009).