



# Identification of a novel, putative cataract-causing allele in *CRYAA* (G98R) in an Indian family

Sathiyavedu T. Santhiya,<sup>1</sup> Torben Söker,<sup>2</sup> Norman Klopp,<sup>3</sup> Thomas Illig,<sup>3</sup> M. V. S. Prakash,<sup>4</sup> Bhavani Selvaraj,<sup>1</sup> Puthiya M. Gopinath,<sup>5</sup> Jochen Graw<sup>2</sup>

<sup>1</sup>Dr. ALM. Postgraduate Institute of Basic Medical Sciences, Department of Genetics, University of Madras, Taramani, Chennai, India; <sup>2</sup>GSF-National Research Center for Environment and Health, Institutes of <sup>2</sup>Developmental Genetics and of <sup>3</sup>Epidemiology, Neuherberg, Germany; <sup>4</sup>Regional Institute of Ophthalmology, Governmental Eye Hospital, Egmore, Chennai; <sup>5</sup>Kasturba Medical College (KMC), Life Science Centre, Manipal Academy of Higher Education (MAHE), Manipal, India

**Purpose:** The aim of the present study was to investigate the molecular basis underlying a nonsyndromic presenile autosomal dominant cataract in a three-generation pedigree. The phenotype was progressive from a peripheral ring-like opacity to a total cataract with advancing age from teenage to adulthood. The visual impairment started as problem in distant vision at the age of 16 years, to diminishing vision by the age of 24.

**Methods:** Clinical interventions included complete ophthalmological examination, a collection of case history, and pedigree details. Blood samples were collected from available family members irrespective of their clinical status. A functional candidate gene approach was employed for PCR screening and sequencing of the exons and their flanking regions of *CRYGC*, *CRYGD*, and *CRYAA* genes. For structural consequences of the mutated  $\alpha$ A-crystallin we used the bioinformatics tool of the ExPASy server.

**Results:** Sequence analysis of *CRYGC* and *CRYGD* genes excluded possible causative mutations but identified known polymorphisms. Sequencing of the exons of the *CRYAA* gene identified a sequence variation in exon 2 (292 G->A) with a substitution of Gly to Arg at position 98. All three affected members revealed this change but it was not observed in the unaffected father or sister. The putative mutation obliterated a restriction site for the enzyme *Bst*DSI. The same was checked in controls representing the general population of the same ethnicity (n=30) and of randomly selected DNA samples from ophthalmologically normal individuals from the population-based KORA S4 study (n=96). Moreover, the Gly at position 98 is highly conserved throughout the animal kingdom. For the mutant protein, the isoelectric point was raised from pH 5.77 to 5.96. Moreover, an extended  $\alpha$ -helical structure is predicted in this region.

**Conclusions:** The G98R mutation segregates only in affected family members and is not seen in representative controls. It represents very likely the fourth dominant cataract-causing allele in *CRYAA*. In all reported alleles the basic amino acid Arg is involved, suggesting the major importance of the net charge of the  $\alpha$ A-crystallin for functional integrity in the lens.

Diverse cataract mutations have been characterized in man and mouse over the last 10 years. They demonstrate a broad spectrum of genetic and phenotypical variety. However, there are no obvious genotype-phenotype correlations possible. From the biochemical function of the encoded proteins, at least five groups might be distinguished (for a recent review see [1]):

transcription factors, encoded by *FOXE3*, *MAF*, *PAX6*, *PITX3*, *SIX5*, and *SOX2*; membrane proteins, encoded by *GJA3*, *GJA8*, *LIM2*, and *MIP*; enzymes, encoded by *GALK1*, or metabolic disorders such as hyperferritinemia; intermediate filament proteins, encoded by *BFSP1* and *BFSP2*; and structural proteins (the crystallins), encoded by at least 16 genes for  $\alpha$ -,  $\beta$ -, and  $\gamma$ -crystallins.

The analysis of congenital (mainly dominant) cataracts revealed an unexpected high number of mutations in genes coding for  $\gamma$ -crystallins, and to a lesser extent in those genes

coding for  $\alpha$ - and  $\beta$ -crystallins. Crystallins are considered to act mainly as structural proteins of the lens; however, some of them have also been detected in other ocular tissues and other organs [2-4].

Although the crystallins are recognized as highly conserved proteins among the vertebrate species, a significant number of polymorphisms exists in the human population [5-7] and among mouse strains [8]. The present paper demonstrates clinical data for a presenile, peripheral, ring-like lens opacity in 3 affected patients of an Indian family. Since the family size did not permit linkage analysis, a functional candidate gene approach was attempted towards the identification of the underlying molecular lesion, which resulted in the identification of a new cataract-causing allele of the *CRYAA* gene (encoding  $\alpha$ A-crystallin).

## METHODS

In 2002, our ongoing study registered a 24-year-old female proband (CCE20; III-2) with a complaint of diminishing vision at the Regional Institute of Ophthalmology (RIO), Government Eye Hospital, Chennai, India. The proband and her relatives were examined by a senior pediatric ophthalmolo-

---

Correspondence to: Prof. Dr. Jochen Graw, GSF-National Research Center for Environment and Health, Institute of Developmental Genetics, D-85764 Neuherberg, Germany; Phone: +49-89/3187-2610; FAX: +49-89/3187-4620; email: [graw@gsf.de](mailto:graw@gsf.de)

gist (MVSP) with a slit-lamp (Zeiss, Oberkochen, Germany). The case history presented defective vision since the age of 17 years, and slit lamp examination revealed total opacity with severe loss of vision. There was no other associated ocular disorder of either anterior or posterior segment. The proband was posted for cataract surgery at the age of 25 years at the same hospital. Her children are said to be normal although they were not examined clinically.

Family history revealed a four-generation pedigree (Figure 1B). In particular, her mother (II-1) had surgery for cataract extraction at the age of 35 years. The proband's younger brother (16 years old [III-3]) declared himself to have clear vision. However, when examined through a slit lamp, he presented a peripheral ring-like opacity. Accordingly, he was advised to have regular periodic check ups. The father (II-2) and one other female sib (III-1) have normal vision. The study adopted the tenets of the Declaration of Helsinki, as family members were enlightened about the study, its outcome and their role in regional language prior to seeking informed consent as per standard norms. The study was also approved by the Institutional Ethical Committee of Dr. ALM PGIBMS, University of Madras, India.

Blood samples (5-10 ml) were collected from all three affected family members and the available unaffected members (father and one unaffected sib). Genomic DNA was isolated as described previously [9] and amplified by PCR for the exons (and their flanking regions) of the *CRYGC*, *CRYGD* [7], and *CRYAA* genes [10]. PCR products were checked in 1.5% agarose gels and purified through Nucleospin columns (Macherey and Nagel, Düren, Germany). Sequencing was done either commercially (SequiServe, Vaterstetten, Germany) or at the Genome Analysis Center of the GSF (ABI3730; Applied Biosystems, Darmstadt, Germany) according to standard procedures.

The mutation was confirmed by the presence/absence of the cleavage site for the restriction enzyme *Bst*DSI. As controls, 30 ethnically matched healthy individuals were used as well as 96 randomly chosen, ophthalmologically normal, individuals of the KORA Survey 4 (Cooperative Health Research in the Augsburg, Germany Region), which studied a population-based sample of 4,261 subjects aged 25-74 years during the years between 1999-2001 [11].

Secondary structure predictions of the altered protein were analyzed using the Bioinformatics tool of the ExPASy proteomics server. To predict the secondary structure we used the GOR4 prediction method [12].

## RESULTS

**Case history:** The proband, a female of age 24 years (CCE20; III-2; Figure 1B), was registered at RIO, the Government Eye Hospital of Chennai (India), with a problem of diminishing vision. Her history revealed defective vision since her teens. Upon clinical examination through a slit lamp, a total opacity leading to severe loss of vision was documented. She was posted for cataract surgery at the age of 25. She is married to her cousin and has two children of age 5 and 2 years, respectively. They are said to be normal, although not clinically ex-

amined. Her father (CCE20; II-2) and her sister (CCE20; III-1) are said to be normal with no visual impairment. In contrast, her mother (CCE20; II-1) had a complaint of poor vision and hence underwent cataract surgery at the age of 35. The phenotype could not be documented. When sibs were examined, a male sib of 16 years (CCE20; III-3) had clear vision, however, he revealed a peripheral ring-like opacity upon slit lamp examination after pupil dilatation (Figure 1A). He was advised to have periodic ophthalmic checkups in 2002. Since that date, he expressed a problem of poor distant vision. No other ocular disorder of either anterior or posterior segment was documented. There was no association of systemic/metabolic disorders (the pedigree of the family is shown in Figure 1B).

**Molecular genetics:** Because of the small family size, we performed a functional candidate gene analysis instead of

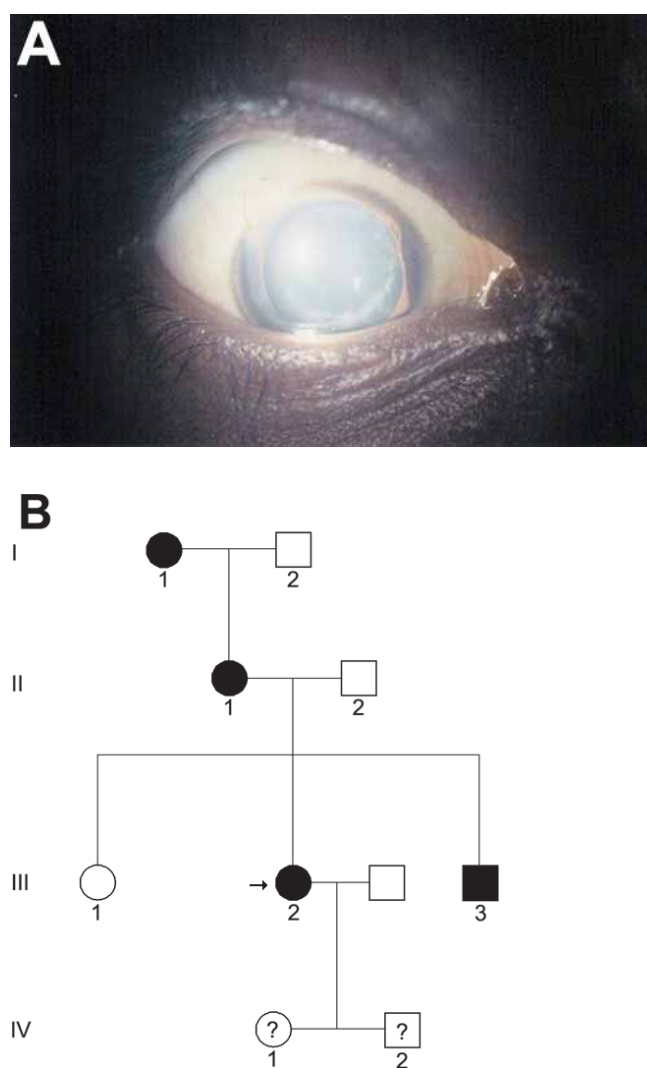


Figure 1. Typical clinical features of pedigree CCE20. A: A peripheral, ring like opacity was observed in a 16-year-old boy (III-3). B: The family history demonstrated that the cataract was present in at least 3 generations (the proband is marked with an arrow). However, blood samples could be collected only from generations II and III.

linkage analysis. Since most hereditary cataracts are caused by mutations in the *CRYGC* and *CRYGD* genes (coding for  $\gamma$ C- and  $\gamma$ D-crystallin, respectively), both genes were checked first. In the proband, no alteration was observed in the *CRYGC* gene compared to the database. However, in *CRYGD* two

changes were found in intron 2 (IVS2+30; 517 T->C and IVS2+83; 570 C->T; K0 3005.1).

Several changes were found in the *CRYAA* gene encoding  $\alpha$ A-crystallin, which was next examined because of its frequent involvement in hereditary cataracts. Two single base


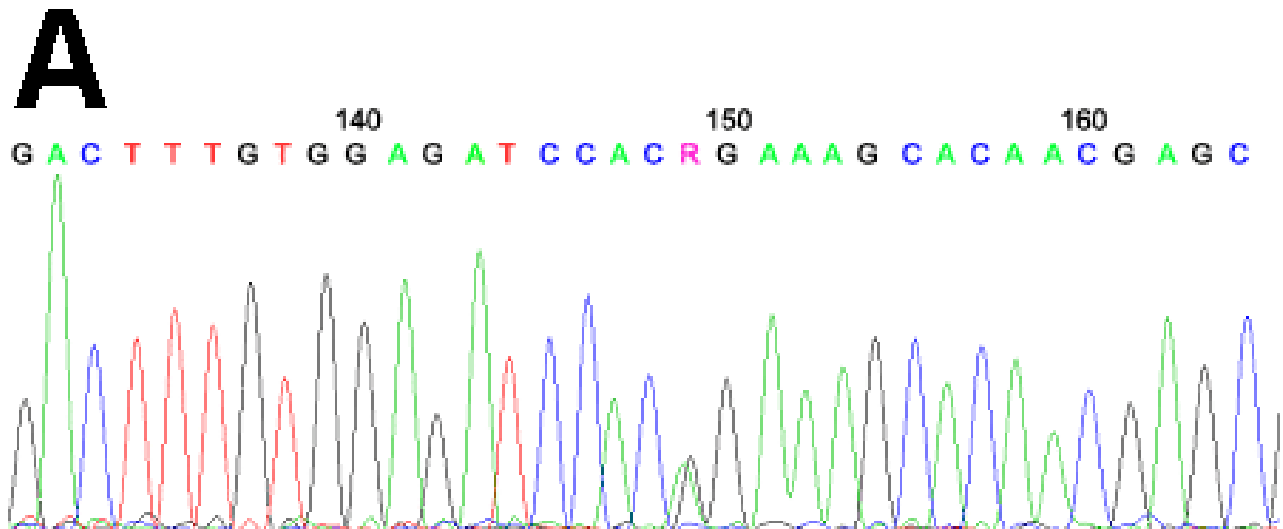
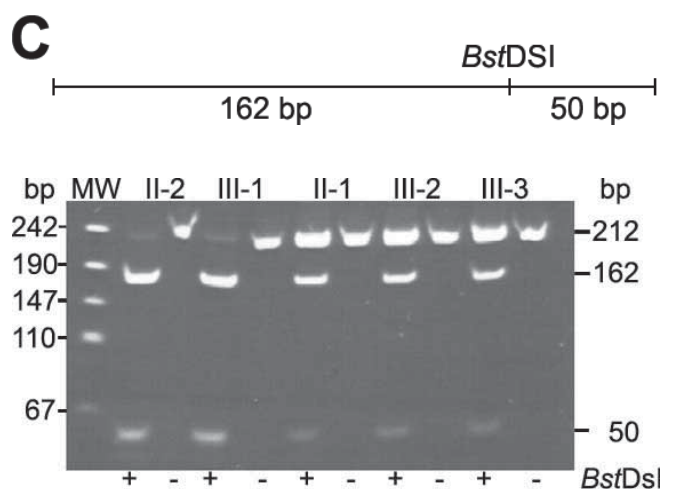


Figure 2. The *CRYAA* mutation in family CCE20. **A:** A partial fragment of the second exon of the *CRYAA* gene is given at sequence position 149 (position 291 in *CRYAA* exon 2, counting the A of the ATG start codon as number 1), the heterozygous situation of the proband is obvious (red arrow). **B:** A partial fragment of the corresponding genomic sequence of the *CRYAA* gene at the end of exon 2 is given. The mutated sequence is shown. The underlined bases (CCACGG) define a *Bst*DSI restriction site, which is destroyed by the mutation. The wild-type base and amino acid are marked in green, and the mutated forms in red. **C:** A schematic overview of exon 2 of the *CRYAA* gene is given indicating the position of the *Bst*DSI restriction site leading to two fragments of 162 and 50 bp. The fragment of 212 bp reflects the mutated form. Exon 2 of the *CRYAA* gene was amplified in family CCE20 and digested by *Bst*DSI. The fragments were analyzed on an agarose gel. The larger fragment of 212 bp can be observed in the affected family members only. The two smaller fragments are present in all family members (II-2, healthy father; III-1, healthy sister; II-1, affected mother; III-2, affected proband; III-3, affected sib).



pair insertions were found in the first intron (insG, +10; insC, -36), and a G->C exchange at +27 in the second intron. Because these alterations occur in the introns only, they are not considered to be causative for the cataracts in the family. It should be noted that all affected members (II-1, III-2, and III-3) have these alterations.

Additionally, we also observed a mutation in the coding region of the *CRYAA* gene. In exon 2 of the *CRYAA* gene, a heterozygous mutation was found in the proband (III-2; 291 G->A; Figure 2A,B). The mutation was confirmed by a *Bst*DS1 digest of the PCR-amplified exon 2 of *CRYAA*. The same alteration was found in the other two family members who were also affected (her affected mother [II-1], and brother [III-3]). This was confirmed by sequencing with the reverse primer. In contrast, the mutation was not observed in the proband's healthy father (II-2) and her sister (III-1; Figure 2C). Finally, this *Bst*DS1 restriction site was not found in 30 randomly selected human DNA samples of Indian origin and in 96 healthy persons collected in the Augsburg, Germany region (data not shown). DNA translation programs predict an exchange of the highly conserved Gly at amino acid position 98 to Arg (G98R). Gly is present at this position in all available sequences (mouse, pan, bovine, dog, chick, zebrafish, and *Xenopus*).

*In-silico protein analysis:* An initial attempt to understand the underlying molecular mechanisms was derived from the computer-assisted analysis of the structure of the mutated G98R  $\alpha$ A-crystallin. Using the proteomics program of the ExPASy proteomics server, we compared several features between the wild-type and the mutant protein. Since no major differences were observed concerning the hydrophobicity of the two proteins, it was calculated that the isoelectric point was shifted from pH 5.77 in the wild-type protein up to pH 5.96 in the mutant  $\alpha$ A-crystallin due to an exchange of the neutral Gly by the basic Arg. It is very likely that the impact of this alteration in the immediate neighborhood of the exchanged amino acid might be much stronger. Therefore, it was not surprising that changes in the secondary structure are predicted, particularly an extension of the first  $\alpha$ -helical region from amino acids 94-97 in the wild type to amino acids 93-99 in the mutant form (the overall increase is from 11.0% in the wild type to 12.7% in the mutant). The remaining flanking random-coil regions are correspondingly decreased (from 74.6% in the wild type to 72.8% in the mutant) and the extended  $\beta$ -sheets remain unaffected (14.5%).

## DISCUSSION

In this communication, we describe a young lady, her mother and a brother suffering from an isolated form of presenile cataract. Her father and the sister are healthy with normal vision. The affected family members had no other ocular defects. Because of the small size of the family, linkage analysis could not be attempted. Therefore, we molecularly analyzed functional candidate genes and identified a mutation in the second exon of the *CRYAA* gene (G98R). Since this mutation segregates perfectly within this family and could not be found in 30 control subjects of Indian origin or in 96 healthy subjects from the region of Augsburg, Germany, we considered this new al-

lele as probable causative molecular lesion for the observed clinical findings.

Earlier reports [9,13,14] on dominant cataracts caused by other *CRYAA* alleles depicted three missense mutations (R21L, R49C, and R116C). Litt et al. [13] described a mutation in a family wherein the phenotype was variable with some of the family members presenting associations with microcornea. Adults in their late thirties developed cortical and posterior subcapsular opacities. Consequently, the time of surgery varied from childhood to late adulthood. The pedigree described here exhibits a cortical opacity in their teenage years, which subsequently progressed to total opacity with diminishing vision.

Interestingly, a complete list of the allelic series of *CRYAA* mutations demonstrates their diversity, since one of the *CRYAA* mutations (W9X) exhibits a recessive mode of inheritance [15]. This genetic diversity is also reflected in the mouse, where the knock-out mutation shows the cataract phenotype in the homozygous null state only [16]. Two additional mouse cataract mutants have been described so far: one suffers from a dominant mutation (V124E [17]), the other from a recessive form (R54H [18]). However, the position of the mutation in the patient reported here lies in the  $\alpha$ A-crystallin core domain, which is obviously very important for the structural integrity of the protein. This hypothesis is further supported by the fact that the Gly residue at position 98 is conserved among 28 mammalian species and in chick and frog [19].

The transparency and high refractive index of the lens are achieved by the precise architecture of the fiber cells and the homeostasis of the lens proteins in terms of their concentration, stability, and supramolecular organization. There are several genes coding for structural proteins; in particular, the crystallins have been demonstrated to be involved in cataractogenesis in human as well as in model organisms like the mouse (for a recent review see [1]). Most of these genes are expressed predominantly in the lens, and a mutation in any one of these genes would be a reasonable explanation for the cataract phenotype. Of the three crystallins, the  $\alpha$ A-crystallin shows a striking sequence similarity to small heat-shock proteins. It acts as a molecular chaperone and is thereby stabilizing, and maintains the integrity of lens fiber cells and their homeostasis from various insults (for a recent review see [20]). However, it should be considered that various lower vertebrates (like the gecko and bony fishes) keep their lenses transparent with no, or hardly any,  $\alpha$ A-crystallin being present [21].

$\alpha$ A-crystallin is almost exclusively expressed in the eye lens and serves in mixed complexes with  $\alpha$ B-crystallin to maintain lens transparency by preventing old and denaturing proteins from aggregating. Therefore, the observed unique mutation in the *CRYAA* gene is considered to be causative for the cataract in family CCE20.

Either loss of chaperone activity and/or an increased tendency of the mutant  $\alpha$ A-crystallin to form aggregates by virtue of altered positive charge and gain of sulfhydryl group has been speculated towards molecular pathogenesis [13]. Another hypothesis highlights the mechanism underlying the pathological process, focusing on the fact that  $\alpha$ -crystallins have

shown a strong tendency to maintain their net charge constant through evolution [22]. Surprisingly, all dominant mutations reported up to now fit this hypothesis, because in all cases the basic amino acid Arg is involved, either it is exchanged by a neutral one or substituted instead of a neutral one. Several other additional mechanisms may also be considered. Detailed biochemical investigations demonstrated for the R116C mutant alterations in the protein-protein interaction, particularly a decreased interaction with  $\beta$ B2- and  $\gamma$ C-crystallins, but an increased interaction with  $\alpha$ B-crystallin and HSP27 [23]. The R49C mutation is located outside the phylogenetically conserved “ $\alpha$ -crystallin core domain”, and the mutant protein was abnormally localized and failed to protect staurosporine-induced apoptotic cell death.

The pathogenicity of this putative mutation remains to be understood. Since biochemical data are not yet available, only theoretical hypotheses can be made. Besides, an increase in the isoelectric point (and the altered net charge of the protein) and an extension of the  $\alpha$ -helical domain around the mutated region most likely influences the structure in the neighborhood. Therefore, the possibility of an altered protein-protein interaction of the mutant protein is very likely. It may be speculated that the mutant  $\alpha$ A-crystallin (G98R) might lead to an impaired chaperone activity, resulting in the onset of cataract as a presenile type in family CCE20.

It may be argued that the putative mutation is benign, since the affected individuals do not suffer from visual impairment until their teens, however, with advancing age, the pathogenicity shows up since the altered CRYAA (G98R) probably loses its integrity as a molecular chaperone, giving way to protein aggregates and consequent opacities. Therefore, the possibility of an altered protein-protein interaction of the mutant protein is very likely. It may therefore be speculated that the mutant CRYAA (G98R) might lead to impaired chaperone activity, resulting in the onset of cataract as a presenile type in family CCE20.

In conclusion, mutations in the CRYAA-encoding gene lead to diverse phenotypes with respect to the form of cataracts, time of onset, and mode of inheritance.

#### ACKNOWLEDGEMENTS

The excellent technical assistance of Erika Bürkle and Monika Stadler (GSF Neuherberg) is gratefully acknowledged. Oligonucleotides were synthesized by Utz Linzner, GSF-Institute of Experimental Genetics. The extended cooperation of family members of pedigree CCE20 is gratefully acknowledged. Supported in part by the German Federal Ministry of Research and Technology, Grant BMBF/DLR IND 03/001 (JG) and the Department of Biotechnology, Government of India, Proj. No. BT/IN/FRG/JRS/2003-04, India (STS and PMG).

#### REFERENCES

- Graw J. The genetic and molecular basis of congenital eye defects. *Nat Rev Genet* 2003; 4:876-88.
- Magabo KS, Horwitz J, Piatigorsky J, Kantorow M. Expression of betaB(2)-crystallin mRNA and protein in retina, brain, and testis. *Invest Ophthalmol Vis Sci* 2000; 41:3056-60.
- Runkle S, Hill J, Kantorow M, Horwitz J, Posner M. Sequence and spatial expression of zebrafish (*Danio rerio*) alphaA-crystallin. *Mol Vis* 2002; 8:45-50.
- Horwitz J. Alpha-crystallin. *Exp Eye Res* 2003; 76:145-53.
- Heon E, Priston M, Schorderet DF, Billingsley GD, Girard PO, Lubsen N, Munier FL. The gamma-crystallins and human cataracts: a puzzle made clearer. *Am J Hum Genet* 1999; 65:1261-7.
- Santhiya ST, Manisastry SM, Rawlley D, Malathi R, Anishetty S, Gopinath PM, Vijayalakshmi P, Namperumalsamy P, Adamski J, Graw J. Mutation analysis of congenital cataracts in Indian families: identification of SNPS and a new causative allele in CRYBB2 gene. *Invest Ophthalmol Vis Sci* 2004; 45:3599-607.
- Santhiya ST, Shyam Manohar M, Rawlley D, Vijayalakshmi P, Namperumalsamy P, Gopinath PM, Loster J, Graw J. Novel mutations in the gamma-crystallin genes cause autosomal dominant congenital cataracts. *J Med Genet* 2002; 39:352-8.
- Graw J, Neuhauser-Klaus A, Klopp N, Selby PB, Loster J, Favor J. Genetic and allelic heterogeneity of Cryg mutations in eight distinct forms of dominant cataract in the mouse. *Invest Ophthalmol Vis Sci* 2004; 45:1202-13.
- Miller SA, Dykes DD, Polesky HF. A simple salting out procedure for extracting DNA from human nucleated cells. *Nucleic Acids Res* 1988; 16:1215.
- Graw J, Klopp N, Illig T, Preising MN, Lorenz B. Congenital cataract and macular hypoplasia in humans associated with a de novo mutation in CRYAA and compound heterozygous mutations in P. Graefes Arch Clin Exp Ophthalmol 2006; Feb 2:1-8 [Epub ahead of print].
- Illig T, Bongardt F, Schopfer A, Holle R, Muller S, Rathmann W, Koenig W, Meisinger C, Wichmann HE, Kolb H, KORA Study Group. The endotoxin receptor TLR4 polymorphism is not associated with diabetes or components of the metabolic syndrome. *Diabetes* 2003; 52:2861-4.
- Combet C, Blanchet C, Geourjon C, Deleage G. NPS@: network protein sequence analysis. *Trends Biochem Sci* 2000; 25:147-50.
- Litt M, Kramer P, LaMorticella DM, Murphey W, Lovrien EW, Weleber RG. Autosomal dominant congenital cataract associated with a missense mutation in the human alpha crystallin gene CRYAA. *Hum Mol Genet* 1998; 7:471-4.
- Mackay DS, Andley UP, Shiels A. Cell death triggered by a novel mutation in the alphaA-crystallin gene underlies autosomal dominant cataract linked to chromosome 21q. *Eur J Hum Genet* 2003; 11:784-93.
- Pras E, Frydman M, Levy-Nissenbaum E, Bakhan T, Raz J, Assia EI, Goldman B, Pras E. A nonsense mutation (W9X) in CRYAA causes autosomal recessive cataract in an inbred Jewish Persian family. *Invest Ophthalmol Vis Sci* 2000; 41:3511-5.
- Brady JP, Garland D, Douglas-Tabor Y, Robison WG Jr, Groome A, Wawrousek EF. Targeted disruption of the mouse alpha A-crystallin gene induces cataract and cytoplasmic inclusion bodies containing the small heat shock protein alpha B-crystallin. *Proc Natl Acad Sci U S A* 1997; 94:884-9.
- Graw J, Loster J, Soewarto D, Fuchs H, Meyer B, Reis A, Wolf E, Balling R, Hrabe de Angelis M. Characterization of a new, dominant V124E mutation in the mouse alphaA-crystallin-encoding gene. *Invest Ophthalmol Vis Sci* 2001; 42:2909-15.
- Chang B, Hawes NL, Roderick TH, Smith RS, Heckenlively JR, Horwitz J, Davisson MT. Identification of a missense mutation in the alphaA-crystallin gene of the lop18 mouse. *Mol Vis* 1999; 5:21.
- de Jong WW, Zweers A, Versteeg M, Nuy-Terwindt EC. Primary

- structures of the alpha-crystallin A chains of twenty-eight mammalian species, chicken and frog. *Eur J Biochem* 1984; 141:131-40.
20. Augusteyn RC. alpha-crystallin: a review of its structure and function. *Clin Exp Optom* 2004; 87:356-66.
  21. de Jong WW, Caspers GJ, Leunissen JA. Genealogy of the alpha-crystallin—small heat-shock protein superfamily. *Int J Biol Macromol* 1998; 22:151-62.
  22. Berengian AR, Bova MP, Mchaourab HS. Structure and function of the conserved domain in alphaA-crystallin. Site-directed spin labeling identifies a beta-strand located near a subunit interface. *Biochemistry* 1997; 36:9951-7.
  23. Fu L, Liang JJ. Detection of protein-protein interactions among lens crystallins in a mammalian two-hybrid system assay. *J Biol Chem* 2002; 277:4255-60.