

A Proof-of principal study using Phase-contrast imaging for the detection of large airway pathologies after lung transplantation

Stephan Umkehrer^{1,*}, Carmela Morrone², Julien Dinkel^{3,4}, Laura Aigner³, Maximilian F. Reiser^{3,4}, Julia Herzen¹, Ali Ö. Yildirim^{2,4}, Franz Pfeiffer^{1,5,+}, and Katharina Hellbach^{3,6,7,+}

¹Chair of Biomedical Physics, Physics Department & Munich School of BioEngineering, Technical University of Munich (TUM), Garching, Germany

²Comprehensive Pneumology Center Munich (CPC-M), Ludwig-Maximilians University Munich, Member of the German Center for Lung Research (DZL), Munich, Germany

³Department of Radiology, University Hospital, Ludwig-Maximilians University Munich, Munich, Germany

⁴Institute of Lung Biology and Disease, Helmholtz Zentrum München, Neuherberg, Germany

⁵Department of Diagnostic and Interventional Radiology, School of Medicine & Klinikum rechts der Isar, Technical University of Munich, Munich, Germany

⁶Department of Diagnostic and Interventional Radiology, University Hospital of Heidelberg, Ruprecht-Karls-University Heidelberg, Heidelberg, Germany

⁷Translational Lung Research Center Heidelberg (TLRC), Ruprecht-Karls-University Heidelberg, German Center for Lung Research (DZL), Heidelberg, Germany

*stephan.umkehrer@ph.tum.de

+These authors contributed equally to this work.

ABSTRACT

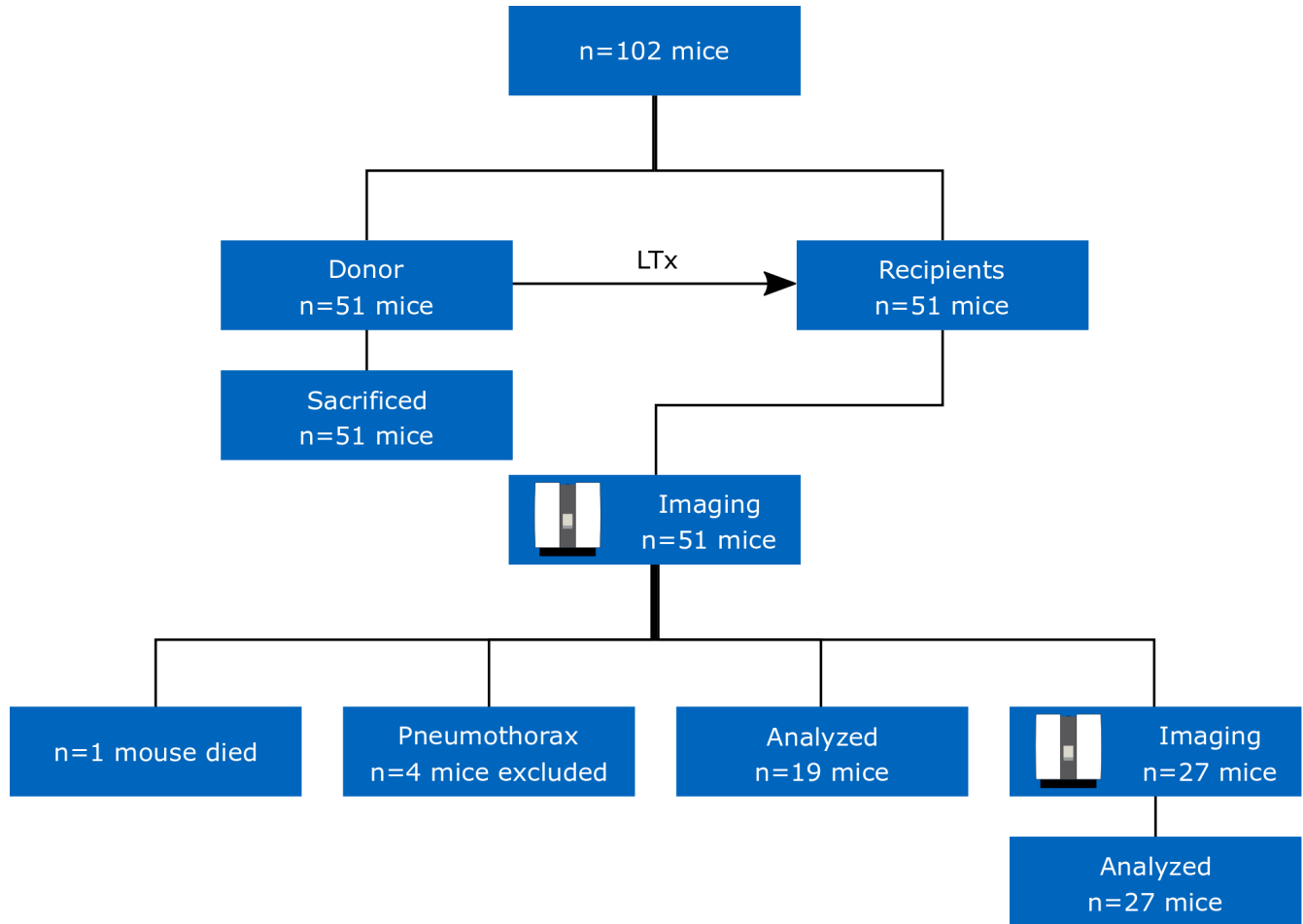


Figure 1. Scheme of the work-flow within this study.

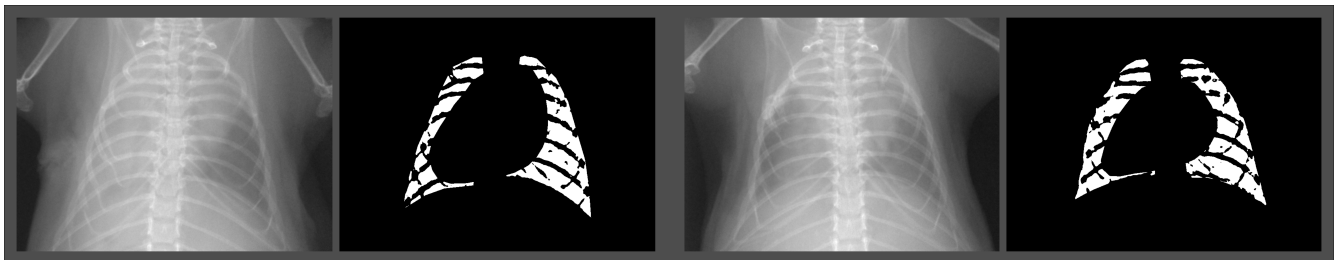


Figure 2. Example for choice of the ROIs for two transplanted mice. The segmentation was performed using MATLAB version R2018b (https://www.mathworks.com/products/new_products/release2018b.html).