



A *de novo* truncating variant in *CSDE1* in an adult-onset neuropsychiatric phenotype without intellectual disability[☆]

Martin Krenn^{a,b}, Sylvia Kepa^a, Gregor Kasprian^c, Korbinian M. Riedhammer^{b,d},
Matias Wagner^{b,e}, Ursula Goedl-Fleischhacker^f, Ivan Milenkovic^{a,*}

^a Department of Neurology, Medical University of Vienna, Vienna, Austria

^b Institute of Human Genetics, Klinikum Rechts der Isar, Technical University of Munich, Munich, Germany

^c Department of Biomedical Imaging and Image-Guided Therapy, Medical University of Vienna, Vienna, Austria

^d Department of Nephrology, Klinikum Rechts der Isar, Technical University of Munich, Munich, Germany

^e Institute of Neurogenomics, Helmholtz Zentrum München, Neuherberg, Germany

^f Department of Psychiatry, Klinikum Landstraße, Vienna, Austria

ARTICLE INFO

Keywords:

CSDE1

Psychosis

Neurodevelopment

Whole-exome sequencing

ABSTRACT

Variants in *CSDE1*, a gene encoding a constrained RNA-binding protein, have recently been associated with a spectrum of neurodevelopmental conditions encompassing autism, seizures and ocular abnormalities. According to previously reported individuals, pathogenic variants in *CSDE1* are typically associated with developmental delay and intellectual disability. Here, we report one individual with normal neurodevelopment and adult-onset neuropsychiatric features (i.e., acute psychosis) due to the novel *de novo* truncating variant c.2272C>T, p.(Gln758*) in *CSDE1* (NM_001242891.1). Neuropsychological assessment confirmed deficits regarding verbal fluency, semantic memory, executive function and processing speed. Overall, our findings expand the phenotypic spectrum of *CSDE1*-related disorder towards the mild end.

1. Introduction

Genes that are functionally involved in posttranscriptional regulation have been associated with a wide spectrum of neurodevelopmental and neuropsychiatric phenotypes (De Rubeis et al., 2014). Owing to the constantly increasing use of next-generation sequencing in clinical practice, the list of underlying genes is growing at a rapid pace (Wang et al., 2020).

CSDE1 encodes the highly constrained RNA-binding protein cold-shock domain-containing E1, which is crucially involved in translationally coupled mRNA turnover (Chang et al., 2004). Truncating variants in *CSDE1* have recently been associated with a range of neurodevelopmental disorders including autism spectrum disorder, intellectual disability, epileptic seizures and various ocular abnormalities. Detailed clinical reports of 17 individuals have been published as a case series along with comprehensive functional analyses, suggesting *CSDE1* as a monogenic disease gene (Guo et al., 2019). Furthermore, one publication described clinical and functional data of one additional case,

indicating dysregulated Wnt/ β -catenin signaling and cellular adhesion as underlying disease mechanisms (El Khouri et al., 2021). Most recently, another paper reported a child with speech and motor delay, intellectual disability and psychiatric symptoms due to a truncating *CSDE1* variant (Gangfuss et al., 2021).

Our case study corroborates the association between variants in *CSDE1* and human disease. Of note, we expand the previously delineated phenotypic spectrum towards the mild end by describing one additional individual with normal neurodevelopment and intellect, in which a severe, late-onset neuropsychiatric manifestation led to genetic testing.

2. Methods

2.1. Clinical data acquisition

After written informed consent was obtained from all participating individuals, blood samples were drawn, and genomic DNA was extracted. The clinical assessment included a detailed medical history, a

[☆] The study was performed in agreement with the ethical standards of the responsible committee on human experimentation (institutional and national) and with the Declaration of Helsinki and was approved by the local ethics committees.

* Corresponding author. Department of Neurology, Medical University of Vienna, 1090, Vienna, Austria

E-mail address: ivan.milenkovic@meduniwien.ac.at (I. Milenkovic).

neurological examination, a neuropsychological assessment, brain magnetic resonance imaging (MRI), a fluorodeoxyglucose positron emission tomography (FDG-PET) scan and electroencephalography (EEG).

2.2. Exome sequencing

Exome sequencing (ES) was performed according to a previously reported protocol and pipeline (Kremer et al., 2017; Krenn et al., 2020). *SureSelect Human All Exon Kit* 60 Mb, V6 (Agilent, Santa Clara, California, USA) was used for exome enrichment. Libraries were sequenced on an *Illumina NovaSeq6000* system (Illumina, San Diego, California, USA). Reads were aligned to the UCSC human reference assembly (hg19). More than 94% of the exome were covered at least 20-fold. Average coverage was more than 105-fold. The standard criteria of the American College of Medical Genetics and Genomics (ACMG) were applied for variant interpretation (Richards et al., 2015). Reported variants were submitted to ClinVar.

3. Clinical report

3.1. Clinical vignette

In our currently 46-year-old female patient of Austrian origin, pregnancy and birth were reported as unremarkable without any relevant complications. Early neurodevelopment was also normal. She was able to sit unsupported at 6 months, to walk unaided at 16 months and to speak a few words at 12 months of age. No syndromic or dysmorphic features were reported. Although there was no evidence of cognitive impairment or developmental delay, the patient was described as a rather anxious, introverted and indecisive person since childhood. Social interactions were mainly limited to close attachment figures (i.e., parents and sibling). Later, she even passed her A-levels (i.e., Austrian

secondary school exit exam), went to university (without obtaining a degree) and eventually worked in a municipal department office.

The patient had a previous history of sensorineural hearing impairment and multiple ocular abnormalities since childhood including pendular nystagmus, cataract, amblyopia, myopia and exotropia. In addition, depressive episodes and anxiety without psychotic symptoms have first been reported in early adulthood.

At the age of 44 years, she was admitted to a psychiatric ward due to a first but severe manifestation of acute psychosis with somatic hallucinations and delusions. Initially, an acute polymorphic psychotic disorder was diagnosed and treated with antipsychotic drugs. Yet, after admission to the hospital, psychotic symptoms progressed rapidly in spite of treatment, and speech problems and a shuffling gait were noted.

A thorough neuropsychological assessment confirmed remarkable deficits in the domains verbal fluency, semantic memory, executive function and processing speed. In contrast, she yielded above-average results regarding general intellectual ability, attention, concentration, abstraction capability, verbal memory, logical reasoning and spatial imagination. Altogether, the neuropsychological findings were considered suggestive of an organic mental disorder. Hence, an early-onset neurodegenerative disorder was among the primary differential diagnoses, so that a comprehensive diagnostic work-up was initiated.

A neurological examination revealed a bilateral postural tremor, but no signs of ataxia, rigidity or bradykinesia. An MRI of the brain showed subtle microangiopathic lesions and a smaller rather verticalized left hippocampus (Fig. 1A). An FDG-PET scan of the brain was also performed and reported as normal. Our patient had no history of epileptic seizures, and routine EEG did not reveal any pathological findings.

During the further disease course, psychotic symptoms could be stabilized with antipsychotic medication and the patient was eventually discharged almost three months after admission. At last follow-up, she had withdrawn her medication, lived alone and used continuous psychotherapy.

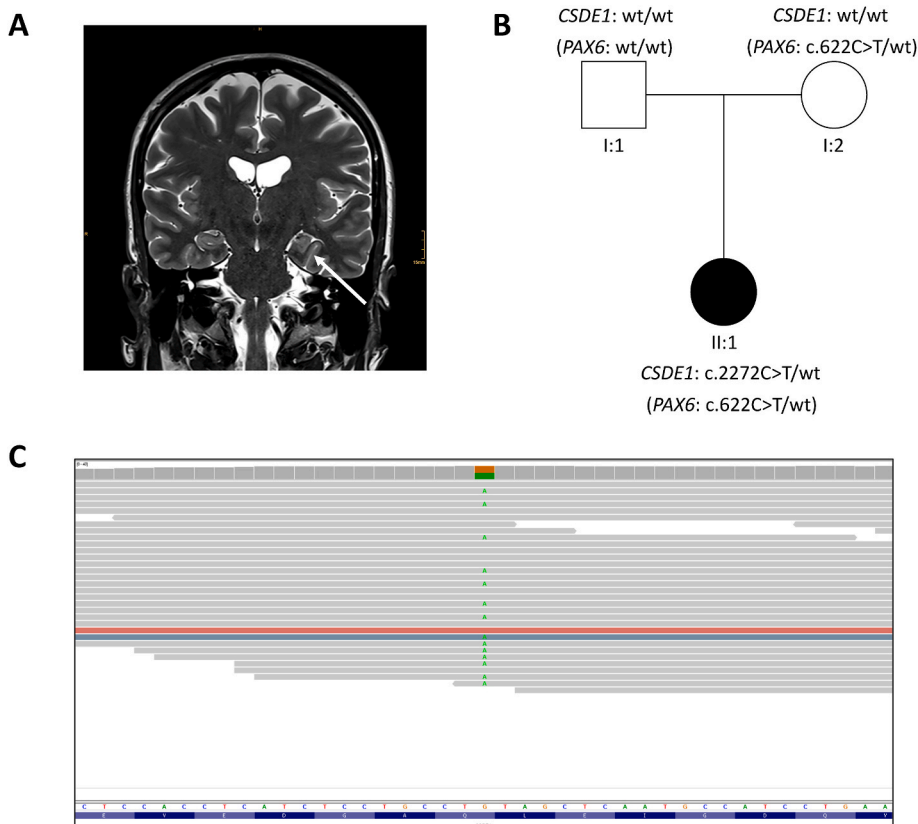


Fig. 1. Imaging and molecular findings in our patient. (A) Coronal T2-weighted MR sequence at 3 T demonstrates a deep and verticalized left collateral sulcus and a smaller rather verticalized left hippocampus (compared to the unremarkable right hippocampus); (B) Pedigree of the family illustrating the *de novo* origin of the pathogenic *CSDE1* variant as well as the *PAX6* variant (in brackets) inherited from the patient's mother; (C) Screenshot from the Integrative Genomics Viewer (IGV) showing the nonsense variant in *CSDE1* detected by ES in the index patient.

3.2. Genetic findings

Due to the complex constellation of symptoms and the lack of an acquired etiology despite a thorough diagnostic work-up, an underlying genetic cause was eventually considered. Diagnostic ES revealed the previously undescribed heterozygous nonsense variant c.2272C>T, p. (Gln758*) in *CSDE1* (NM_001242891.1, NP_001229820.1, ClinVar accession: SCV001430097.1), which could not be identified in both parents by Sanger sequencing, suggesting a *de novo* origin (Fig. 1B+C). Hence, the variant was classified as pathogenic according to ACMG (Richards et al., 2015). The variant was absent from gnomAD (Genome Aggregation Database) and our in-house database comprising >20,000 exome datasets.

In addition, the pathogenic missense variant c.622C>T, p. (Arg208Trp) was detected in *PAX6* (NM_000280.4, NP_000271.1, ClinVar accession: SCV001430017.1) in the patient and her mother in a heterozygous state (Fig. 1B). *PAX6* has been associated with a certain range of ocular abnormalities including nystagmus, aniridia and iris coloboma (Lima Cunha et al., 2019; Vasilyeva et al., 2021).

4. Discussion

In our case study, we report an individual with adult-onset psychosis as well as subtle autistic and neurological features but no intellectual disability, in which diagnostic ES led to the identification of a novel *de novo* variant in *CSDE1*.

Recently, disruptive variants in *CSDE1* have been related to autism spectrum disorder, developmental delay, epilepsy and ophthalmological abnormalities with only a small number of affected individuals reported to date. The initially delineated syndrome appeared to be commonly associated with childhood-onset cognitive impairment, ranging from learning disability to severe motor and speech delay. One adult patient of the previously published cohort was 19 years old at the time of publication and experienced psychiatric symptoms (with a diagnosis of schizophrenia) in early adulthood in addition to pre-existing learning disability (Guo et al., 2019).

Our report further expands the phenotypic spectrum of *CSDE1*-related disorders, as our patient displayed severe and acute psychotic symptoms manifesting at the age of 44 years. Most notably, early psychomotor development was reported as normal, and a detailed neuropsychological assessment even indicated over-average intellectual abilities. We believe that the clinical differences between previously described patients and our case may highlight a reporting bias in the literature with an overrepresentation of infantile-onset neuropediatric phenotypes. It has already been demonstrated for other (neurological) conditions that *de novo* variation may be associated with a later disease onset than previously appreciated (McCormack et al., 2020; Nicolas and Veltman, 2019).

We are aware that existing evidence for an association between variants in *CSDE1* and neuropsychiatric phenotypes is still limited and based on three previous publications. However, given the *de novo* occurrence of truncating variants in neurodevelopmental phenotypes and the gnomAD pLI (probability of loss-of-function intolerance) score of 1, we rather suggest that these variants act as highly penetrant risk factors.

Given the insertion of a stop codon located in the third to last exon, we expect a truncating effect on the protein level. Yet, truncating variants may potentially be associated with nonsense-mediated mRNA decay, eventually resulting in the complete absence of a functioning protein, which obviously limits any conclusions of the variant location on the phenotype (Lykke-Andersen and Jensen, 2015). However, one may argue that the mild phenotype in our case suggests that some protein function may remain because of the C-terminal variant location.

In our patient, a comprehensive diagnostic work-up including clinical examination, different neuroimaging modalities and EEG did not reveal any specific abnormalities. Most notably, an MRI of the brain

showed a smaller and verticalized left hippocampus (incomplete hippocampal inversion) which is generally considered unspecific. Nonetheless, a recent study demonstrated an increased prevalence in patients with schizophrenia, supporting a neurodevelopmental pathogenesis model of psychotic conditions (Roeske et al., 2021).

While severe neuropsychiatric manifestations occurred comparably late in our patient, mild autistic and ophthalmological features were already present in childhood. It can only be speculated that the comparably mild psychiatric manifestations reported in early adulthood may have already represented a *CSDE1*-related manifestation.

Of note, we also detected a pathogenic *PAX6* variant in our patient, which makes it difficult to definitely ascribe specific ocular features to one of the two molecular diagnoses. Hyperopia and strabismus, which are also part of our patient's phenotype (and not noted in the patient's mother), could possibly be related to the *CSDE1* variant (Guo et al., 2019).

Taken all together, we conclude that pathogenic variants in *CSDE1* need to be taken into consideration in cases with adult-onset neuropsychiatric manifestations, also in the absence of intellectual disability. As demonstrated by our case study, additional neurological or imaging abnormalities may be subtle and unspecific.

Author contribution

MK drafted the manuscript and was involved in genetic data analysis. SK, GK and UGF were involved in data acquisition and the clinical management of the patient. KMR and TB were involved in genetic data analysis. MW supervised genetic data analysis. IM was involved in the clinical management of the patient, proposed and supervised the manuscript. All authors critically revised the manuscript.

Funding sources

No targeted funding reported.

5. Data availability statement

Anonymized data not published in this article will be made available by request from the corresponding author.

Declaration of competing interest

Dr. Krenn, Dr. Kepa, Dr. Kasprian, Dr. Riedhammer, Dr. Wagner, Dr. Goedl-Fleischhacker and Dr. Milenkovic report no disclosures.

Acknowledgements

The authors would like to thank the family for participating in the study.

References

- Chang, T.C., Yamashita, A., Chen, C.Y., Yamashita, Y., Zhu, W., Durdan, S., Kahvejian, A., Sonenberg, N., Shyu, A.B., 2004. UNR, a new partner of poly(A)-binding protein, plays a key role in translationally coupled mRNA turnover mediated by the c-fos major coding-region determinant. *Genes Dev.* 18, 2010–2023.
- De Rubeis, S., He, X., Goldberg, A.P., Poultney, C.S., Samocha, K., Cicek, A.E., Kou, Y., Liu, L., Fromer, M., Walker, S., et al., 2014. Synaptic, transcriptional and chromatin genes disrupted in autism. *Nature* 515, 209–215.
- El Khouri, E., Ghoumid, J., Haye, D., Giuliano, F., Drevillon, L., Briand-Suleau, A., De La Grange, P., Nau, V., Gaillon, T., Biennu, T., et al., 2021. Wnt/beta-catenin pathway and cell adhesion deregulation in *CSDE1*-related intellectual disability and autism spectrum disorders. *Mol. Psychiatr.*
- Gangfuss, A., Lochmuller, H., Topf, A., O'Heir, E., Horvath, R., Kolbel, H., Schweiger, B., Schara-Schmidt, U., Roos, A., 2021. A *de novo* *CSDE1* variant causing neurodevelopmental delay, intellectual disability, neurologic and psychiatric symptoms in a child of consanguineous parents. *Am. J. Med. Genet.*
- Guo, H., Li, Y., Shen, L., Wang, T., Jia, X., Liu, L., Xu, T., Ou, M., Hoekzema, K., Wu, H., et al., 2019. Disruptive variants of *CSDE1* associate with autism and interfere with neuronal development and synaptic transmission. *Sci. Adv.* 5, eaax2166.

- Kremer, L.S., Bader, D.M., Mertes, C., Kopajtich, R., Pichler, G., Iuso, A., Haack, T.B., Graf, E., Schwarzmayr, T., Terrile, C., et al., 2017. Genetic diagnosis of Mendelian disorders via RNA sequencing. *Nat. Commun.* 8, 15824.
- Krenn, M., Wagner, M., Hotzy, C., Graf, E., Weber, S., Brunet, T., Lorenz-Depiereux, B., Kasprian, G., Aull-Watschinger, S., Patariaia, E., et al., 2020. Diagnostic exome sequencing in non-acquired focal epilepsies highlights a major role of GATOR1 complex genes. *J. Med. Genet.* 57, 624–633.
- Lima Cunha, D., Arno, G., Corton, M., Moosajee, M., 2019. The spectrum of PAX6 mutations and genotype-phenotype correlations in the eye. *Genes* 10.
- Lykke-Andersen, S., Jensen, T.H., 2015. Nonsense-mediated mRNA decay: an intricate machinery that shapes transcriptomes. *Nat. Rev. Mol. Cell Biol.* 16, 665–677.
- McCormack, M., McGinty, R.N., Zhu, X., Slattery, L., Heinzen, E.L., Consortium, E., Costello, D.J., Delanty, N., Cavalleri, G.L., 2020. De-novo mutations in patients with chronic ultra-refractory epilepsy with onset after age five years. *Eur. J. Med. Genet.* 63, 103625.
- Nicolas, G., Veltman, J.A., 2019. The role of de novo mutations in adult-onset neurodegenerative disorders. *Acta Neuropathol.* 137, 183–207.
- Richards, S., Aziz, N., Bale, S., Bick, D., Das, S., Gastier-Foster, J., Grody, W.W., Hegde, M., Lyon, E., Spector, E., et al., 2015. Standards and guidelines for the interpretation of sequence variants: a joint consensus recommendation of the American College of medical genetics and genomics and the association for molecular pathology. *Genet. Med.* 17, 405–424.
- Roeske, M.J., McHugo, M., Vandekar, S., Ju, Blackford, Woodward, N.D., Heckers, S., 2021. Incomplete hippocampal inversion in schizophrenia: prevalence, severity, and impact on hippocampal structure. *Mol. Psychiatr.*
- Vasilyeva, T.A., Marakhonov, A.V., Voskresenskaya, A.A., Kadyshchev, V.V., Kasman-Kellner, B., Sukhanova, N.V., Katargina, L.A., Kutsev, S.I., Zinchenko, R.A., 2021. Analysis of genotype-phenotype correlations in PAX6-associated aniridia. *J. Med. Genet.* 58, 270–274.
- Wang, T., Hoekzema, K., Vecchio, D., Wu, H., Sulovari, A., Coe, B.P., Gillentine, M.A., Wilfert, A.B., Perez-Jurado, L.A., Kvarnang, M., et al., 2020. Large-scale targeted sequencing identifies risk genes for neurodevelopmental disorders. *Nat. Commun.* 11, 4932.